



Published by DiscoverSys

Unilateral pedicle screw fixation as a less invasive surgical procedure: a case series and literature review



CrossMark

Tjokorda Gde Bagus Mahadewa^{1*}

ABSTRACT

Introduction: The principle of treatment for degenerative spinal diseases when conservative modality failed is surgery. Unilateral pedicle screw fixation is a less invasive methods with clinical outcomes that were similar to a bilateral fixation, especially for lumbar degenerative disease. Improvement of symptoms, neurological outcome and spinal stability is the utmost priority. This was a case series study with five patients with degenerative spine disease from January 2019 - January 2020. The aims are to evaluate unilateral pedicle screw surgery outcomes and elucidate the effectiveness of this method clinically.

Case Description: Five patients aged 40-64 years old involved in this series. Four patients presented with lumbar radiculopathy and one patient with cervical radiculopathy. All experienced weakness (MMT score 2-4) and pain along the affected extremities. Three patients diagnosed with concomitant Herniated Nucleus Pulposus (HNP) and Foraminal Stenosis (FS) based on clinical examination

and Magnetic Resonance Imaging result. The rest of two patients each diagnosed with FS and HNP. Surgery initiated with a midline incision. Muscle ipsilateral to the symptomatic side was dissected and retracted to expose the facet joint and the vertebral lamina. Screws were inserted into the vertebral body and the rod used to connect the screws was bent following the vertebral curvature. Facetectomy or Hemilaminectomy was done to expose and decompress the ipsilateral side's nerve root and intervertebral space. The incision site is then irrigated and closed. All operation was done by the same surgeon. Postoperative clinical outcomes were evaluated for six months after surgery. All patients showed a complete motor improvement and fully relieved from pain.

Conclusion: Unilateral pedicle screw fixation is considered as a less invasive instrumentation system with clinical outcome comparable to bilateral screw fixation.

Keywords: degenerative spinal diseases, unilateral pedicle screw, clinical outcome.

Cite this Article: Mahadewa, T.G.B. 2020. Unilateral pedicle screw fixation as a less invasive surgical procedure: a case series and literature review. *Bali Medical Journal* 9(3): 705-709. DOI: [10.15562/bmj.v9i3.2042](https://doi.org/10.15562/bmj.v9i3.2042)

INTRODUCTION

Pedicle screw fixation is necessary to stabilize the management of vertebrae instability. For a long time, bilateral screw fixation after laminectomy or interbody fusion has been standard surgical management for degenerative lumbar disease.^{1,2} However, there was a downside in doing rigid bilateral fixation. The implanted device may accelerate adjacent segment degeneration and osteoporosis.¹ Unilateral pedicle screw fixation was a relatively less invasive method with similar clinical and radiological outcomes.³⁻⁵ Some studies also reported that unilateral pedicle screw fixation resulted in shorter surgical duration, lower blood loss, and ultimately reduced hospital cost.¹⁻⁴

This paper will elaborate on the author's experience in managing lumbar and cervical degenerative diseases and subsequent Hemilaminectomy and unilateral pedicle screw fixation.

METHODS

Five patients in two institutions were involved in these series, with four patients have lumbar radiculopathy and one patient with cervical radiculopathy (Table 1). Hemilaminectomy and stabilization with unilateral pedicle screws were conducted by the same surgeon (author). Postoperative clinical outcomes were followed up for six months after surgery. This study has been approved by the Committee of Research Ethics of Universitas Udayana/Sanglah Hospital.

Table 1. Patients characteristic

Characteristic	Cases(n=5)
Sex	
Male, n (%)	3 (60)
Female, n (%)	2 (40)
Age, years old (y.o), mean	54.2
≤40, n (%)	1 (20)
>40, n (%)	4 (80)
Length of stay, days, mean	6
Complications, n (%)	0 (0)

¹Department of Neurosurgery, Universitas Udayana/Sanglah Hospital, Bali, Indonesia

*Corresponding to:
Tjokorda Gde Bagus Mahadewa.
Department of Neurosurgery,
Universitas Udayana/Sanglah
Hospital, Bali, Indonesia.
tjokmahadewa@unud.ac.id.

Received: 2020-08-22
Accepted: 2020-09-30
Published: 2020-12-01

Surgical technique

After planning the incision site with a C-Arm, a midline incision was performed. Muscle ipsilateral to the symptomatic side was dissected and retracted to expose the facet joint and the vertebral lamina. Screws were inserted into the vertebral body, and the rod was bent following the vertebral curvature and used to connect the screws. Facetectomy or Hemilaminectomy was done to expose and decompress the ipsilateral side's nerve root and intervertebral space. The incision site is then irrigated and closed.

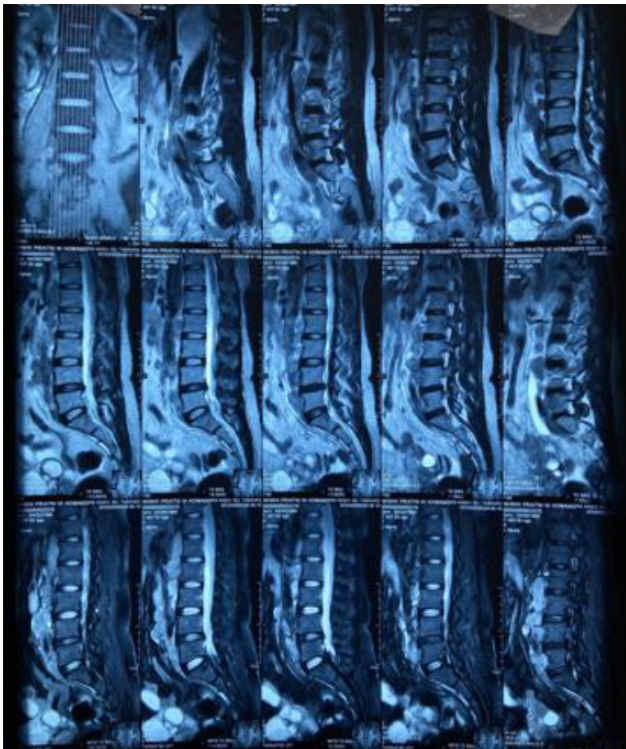


Figure 1. Pre-operative lumbar T2 Sagittal MRI showing herniated disc on the level of L4 – L5 and L5 – S1.

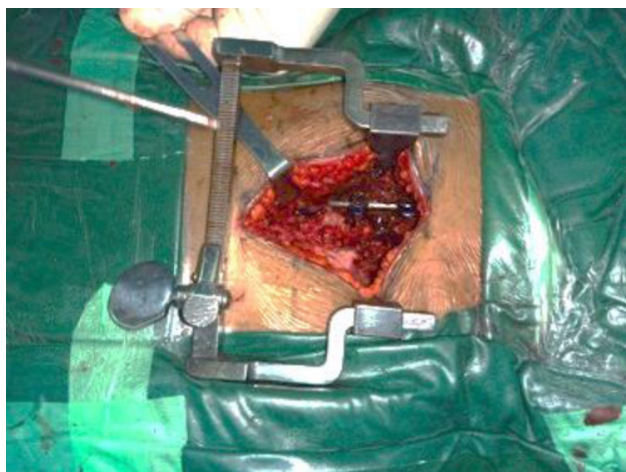


Figure 2. Intraoperative view of unilateral pedicle screw fixation

CASES DESCRIPTION

The first case, a 56-year-old man with symptoms of paresis on his extensor hallucis longus muscle associated with right side disc herniation/herniated nucleus pulposus (HNP) and foraminal stenosis (FS) at L4 – S1, as shown on Magnetic resonance imaging (MRI) (Figure 1). Hemilaminectomy and foraminotomy decompression with unilateral pedicle screw fixation was done with a satisfying outcome. His strength improved from 4 to 5 on the manual muscle testing scale (MMT).

The second case was a 60-year-old male with progressive radicular pain on his left leg and subsequent paresis. The further evaluation established diagnosis of HNP (L1 – L2) as confirmed by MRI study. On initial motoric examination, the patient MMT score was 2/5. Hemilaminectomy with unilateral screw fixation was conducted. The postoperative control radiograph was shown in Figure 4. Two weeks after surgery, the patient gained a significant improvement in muscle strength and a relieved from pain.

The third case was a 51-year-old male with unilateral foraminal stenosis at the cervical level of C5 to C7 (confirmed by MRI study). The patient complained of weakness and pain along his right hand. Postoperative of hemilaminectomy decompression with unilateral pedicle screws, as shown in Figure 5, he completely relieved from his pain with an MMT score of 5/5.

The fourth case was a 64-year-old man with paresis symptoms on his iliopsoas muscle associated with left side disc herniation and foraminal stenosis at L2 – L3. The MMT score was 3/5. Hemilaminectomy with unilateral screw fixation in a patient with left-sided lumbar HNP at the level of L2 – L4. He was completely relieved from the pain with an MMT score of 5/5.

The fifth case was a 40-year-old female with a chief complaint of painful sensation along her left leg with accompanying weakness due to left side HNP and FS at L4 – S1. Hemilaminectomy with unilateral screw fixation (Figure 7) was conducted. Patient experienced pain relieve and significant improvement motor strength.

DISCUSSION

Pedicle screw and rod placement is an essential spinal instrumentation. It is paramount important to achieve a stable fixation to treat surgically provoked or preexisting instability.⁶ Author revealed a good clinical outcome (in the short term) regarding the improvement in MMT of the corresponding extremities (Table 2). However, some issues regarding the excessive rigidity may potentially

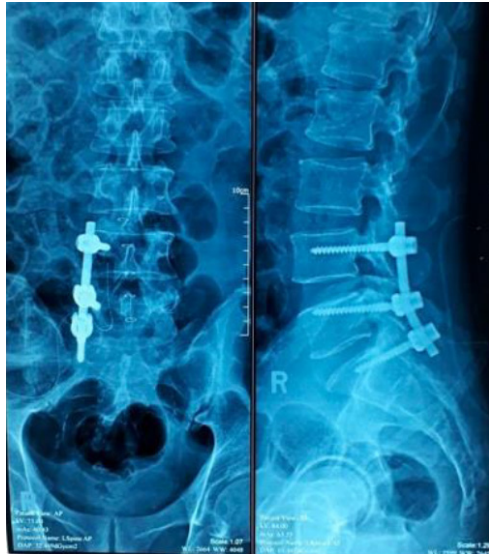

Figure 3. Postoperative anteroposterior and lateral view of lumbar radiograph shows a pedicle screw inserted at the right side of L4, L5, and S1 vertebra.

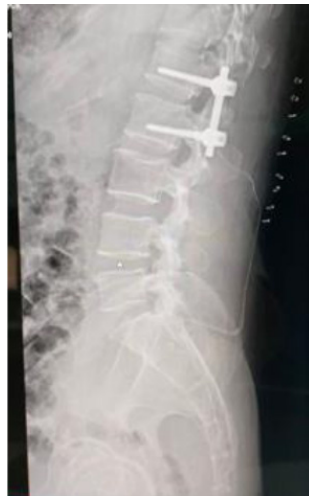

Figure 4. Postoperative lateral view radiograph shows L1 and L2 screw fixation

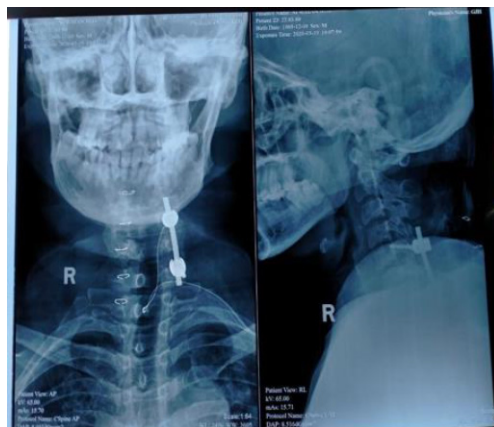

Figure 5. Postoperative Anteroposterior and lateral view of cervical radiograph shows screw fixation on the left side of C5 and C7.

cause adjacent segment degeneration.⁷ Open posterior approach of decompressive laminectomy and subsequent fusion with instrumentation can disrupt the patient's natural anatomy of posterior ligamentous complex and contribute in accelerating the adjacent segment disease.⁸ Kim et al. mentioned that adjacent segment degeneration incidence was lower in unilateral screw fixation.⁷ Furthermore, Kasai et al., in their biomechanical study, demonstrate that together with PEEK cage insertion, a unilateral fixation system is sufficient to maintain stability in fusion of one or two spinal segment.

In the lateral lumbar interbody fusion (LLIF) procedure, there is no significant difference of range of movement (ROM) in all directions between unilateral and bilateral fixation. The unilateral pedicle screw system also decreases the stress shielding effect upon the fixated segment, thus reducing the risk of adjacent disc degeneration with sufficient stability.^{9,10} Although a finite element study found that in trans foraminal interbody fusion (TLIF), bilateral posterior fixation increases construct stabilization compared to unilateral counterpart.¹¹

In terms of fusion rate, there was no significant difference between bilateral and unilateral pedicle screw fixation.^{1,12,13,15} Shen et al. reported that one could achieve comparably similar fusion after unilateral screw fixation than bilateral fixation and it is independent of the fusion segments.⁵ Additionally, the total fusion rate in 6 months is not significantly different between the two instrumentation in the case of one-level lumbar degenerative disease.¹⁴ In their meta-analysis, both Lu et al. and Liu et al. mentioned that no significant difference was found on the Japanese Orthopedic Association (JOA) score between bilateral and unilateral fixation. However, due to considerable heterogeneity in each study involved, this conclusion has to be interpreted with caution.^{1,12} Shen et al. mentioned no difference in terms of visual analog scale (VAS) and Oswestry Disability Index (ODI) in both procedures.¹⁴ Some meta-analysis studies found a similar conclusion that VAS's evaluation at the final follow-up shows a significant difference in favors of unilateral pedicle screw fixation than the bilateral counterpart.^{1,12,13}

Unilateral pedicle fixation also offers other advantages. Some authors found a reduction of the operative blood loss in unilateral pedicle screw fixation than bilateral procedures.^{1,12-16} This procedure is also associated with shorter operative time. However, no significant difference has been found regarding hospital stay for both procedures.^{1,2,14,16} While in one meta-analysis, Liu et al. found that hospital stay is significantly shorter

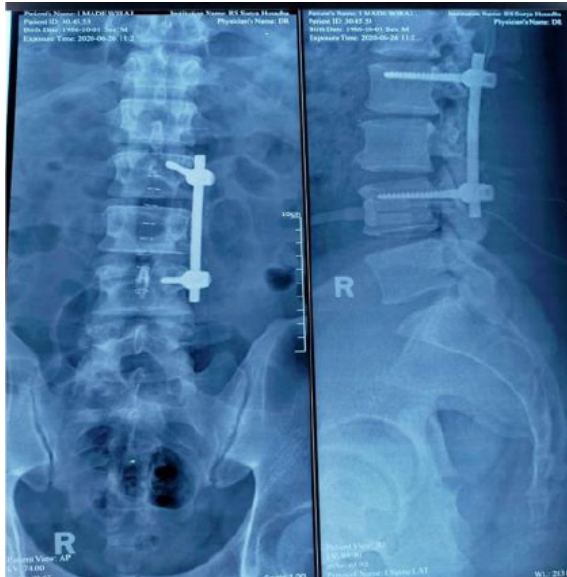


Figure 6. Postoperative Anteroposterior and lateral view of lumbar radiograph shows unilateral pedicle screw inserted at L2 and L4 on the left side

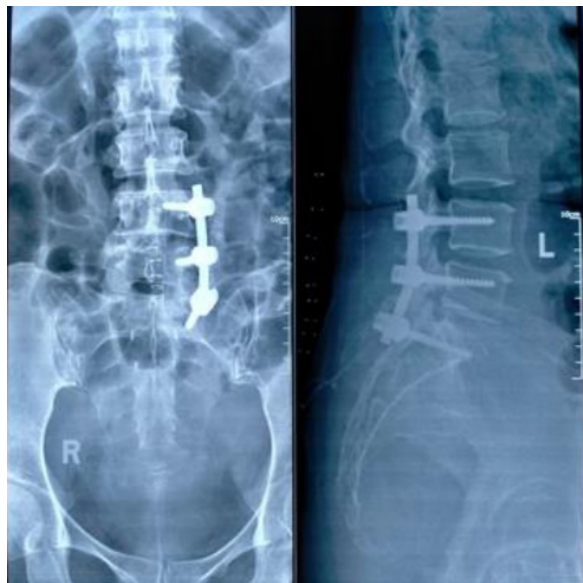

Figure 7. Postoperative anteroposterior and lateral view of lumbar radiograph shows a left side unilateral screw fixation inserted at L4, L5, and S1

for patients with unilateral fixation.¹² Other authors also remark a shorter hospital stay in the unilateral pedicle screw group.¹⁵ Many other reports also conclude hospital and instrumentation cost is significantly lower with unilateral fixation.^{4,15,16}

Even though unilateral pedicle fixation was not associated with more complications, some studies argue that this procedure is more prone to cage migration than bilateral pedicle fixation.^{1,17} Despite that, there is a relatively comparable clinical complication in unilateral pedicle screw fixation such as infection, nerve injury, dural injury and hardware complications compared to bilateral instrumentation.^{12,13,15}

CONCLUSION

Unilateral pedicle screw fixation is considered a less invasive instrumentation system with a comparable clinical outcome to bilateral fixation and instrumentation. Although this article presented a relatively few cases, it strengthens the notion that this method can be used as an alternative in managing patients with degenerative spinal disease.

FUNDING

This study conducted without any grant, third-party support or other source of funding.

CONFLICT OF INTEREST

The author declares no conflict of interest.

REFERENCES

1. Lu P, Pan T, Dai T, Chen G, Shi KQ. Is unilateral pedicle screw fixation superior than bilateral pedicle screw fixation for lumbar degenerative diseases: a meta-analysis. *J Orthop Surg Res.* 2018 Nov 22;13(1):296. doi: 10.1186/s13018-018-1004-x.
2. Mao L, Chen GD, Xu XM, et al. Comparison of Lumbar Interbody Fusion Performed with Unilateral or Bilateral Pedicle Screw. *Orthopedics.* 2013;36:1

Table 2. The summary of the cases

Diagnosis	Spinal Level	Side	Sex/Age	Approach	Treatment	MMT	
						Pre	Post
HNP+FS	L4-S1	Right	Male/56	Unilateral	Hemilaminectomy, Discectomy and Foraminotomy	4	5
HNP	L1-2	Left	Female/60	Unilateral	Hemilaminectomy and Discectomy	2	5
FS	C5-7	Left	Male/51	Unilateral	Hemilaminectomy and Foraminotomy	4	5
HNP + FS	L2-4	Left	Male/64	Unilateral	Hemilaminectomy and Discectomy	3	5
HNP+FS	L4-S1	Left	Female/40	Unilateral	Hemilaminectomy, Discectomy and Foraminotomy	4	5

HNP = Herniated nucleus pulposus, FS = foraminal stenosis, L = lumbar, C = cervical, S = sacral, MMT = manual muscle test

3. Eliades P, Rahal JP, Herrick DB, et al. Unilateral Pedicle Screw Fixation is Associated with Reduced Cost and Similar Outcomes in Selected Patients Undergoing Minimally Invasive Transforaminal Lumbar Interbody Fusion for L4 – 5 Degenerative Spondylolisthesis. *Cureus*. 2015; 7(2): e249
4. Awad BI, Lubelski D, Shin JH, Carmody MA, Hoh DJ, Mroz TE, Steinmetz MP. Bilateral Pedicle Screw Fixation versus Unilateral Pedicle and Contralateral Facet Screws for Minimally Invasive Transforaminal Lumbar Interbody Fusion: Clinical Outcomes and Cost Analysis. *Global Spine J*. 2013 Dec;3(4):225-30. doi: 10.1055/s-0033-1349399.
5. Shen X, Wang L, Zhang H, Gu X, Gu G, He S. e Radiographic Analysis of One-level Minimally Invasive Transforaminal Lumbar Interbody Fusion (MI-TLIF) With Unilateral Pedicle Screw Fixation for Lumbar. *Clin Spine Surg*. 2016;29(1):1–8.
6. Kasai Y, Inaba T, Kato T, Matsumura Y, Akeda K, Uchida A. Biomechanical study of the lumbar spine using a unilateral pedicle screw fixation system. *J Clin Neurosci*. 2010;17(3):364–7.
7. Kim T, Lee BH, Moon S, Lee S, Lee H. Comparison of adjacent segment degeneration after successful posterolateral fusion with unilateral or bilateral pedicle screw instrumentation: a minimum 10-year follow-up. *Spine J*. 2013;13(10):1208–16.
8. Du JY, Kiely PD, Al Maaieh M, Aichmair A, Huang RC. Lateral lumbar interbody fusion with unilateral pedicle screw fixation for the treatment of adjacent segment disease: a preliminary report. *J Spine Surg*. 2017 Sep;3(3):330-337. doi: 10.21037/jss.2017.06.17.
9. Godzik J, Campo EM, Newcomb AG, et al. Biomechanical Stability Afforded by Unilateral vs. Bilateral Pedicle Screw Fixation with and without Interbody Support Using Lateral Lumbar Interbody Fusion. *World Neurosurgery*. 2018; DOI: [10.1016/j.wneu.2018;02.053](https://doi.org/10.1016/j.wneu.2018;02.053)
10. Goel VK, Lim HT, Gwon J, et al. Effects of rigidity of an internal fixation device. A comprehensive biomechanical investigation. *Spine (Phila Pa 1976)*. 1991; S155–61.
11. Ambati D V, Wright EK, Lehman RA, Kang DG, Wagner SC, Dmitriev AE. Bilateral pedicle screw fixation provides superior biomechanical stability in transforaminal lumbar interbody fusion: a finite element study. *Spine J*. 2014.
12. Liu H, Xu Y, Yang S, Wang T, Wang H, Liu F, et al. Unilateral versus bilateral pedicle screw fixation with posterior lumbar interbody fusion for lumbar degenerative diseases. *Medicine*. 2017; 96:21
13. Wang L, Wang Y, Li Z, Yu B, Li Y. Unilateral versus bilateral pedicle screw fixation of minimally invasive transforaminal lumbar interbody fusion (MIS-TLIF): a meta-analysis of randomized controlled trials. *BMC surgery*. 2014;1–7.
14. Shen X, Zhang H, Gu X, Gu G, Zhou X, He S. Unilateral versus bilateral pedicle screw instrumentation for single-level minimally invasive transforaminal lumbar interbody fusion. *J Clin Neurosci*. 2014;8–12.
15. Suk KS, Lee HM, Kim NH. Unilateral Versus Bilateral Pedicle Screw Fixation in Lumbar Spinal Fusion. *Spine*. 2000;25(14):1843–7.
16. Hu X-Q, Wu X-L, Xu C, Zheng X-H, Jin Y-L, et al. A Systematic Review and Meta-Analysis of Unilateral versus Bilateral Pedicle Screw Fixation in Transforaminal Lumbar Interbody Fusion. *PLoS ONE*. 2014;9(1):e87501
17. Aoki Y, Yamagata M, Nakajima F, et al. Examining Risk Factors for Posterior Migration of Fusion Cages Following Transforaminal Lumbar Interbody Fusion: a Possible Limitation of Unilateral Pedicle Screw Fixation. *J Neurosurg Spine*. 2010;13:381 – 387.



This work is licensed under a Creative Commons Attribution