



Published by DiscoverSys

Role of PRP (platelet-rich plasma) in alopecia areata: A literature review



CrossMark

Ni Wayan Eka Ciptasari^{1*}

ABSTRACT

Alopecia areata (AA) is an autoimmune disease that causes hair loss, and its specific cause is not fully determined. This disease affects the patients physically, psychologically, and cosmetically. Treatment of AA is not curative, but controls or limits the disease course. Most treatment modalities are an immunosuppressive or immunomodulatory agent, which are associated with increased side effects. PRP has been used in aesthetics and dermatology, especially for wound repair. Improvement characterized by

hair growth has been reported in several studies. Hair growth improvement with PRP is an effective procedure for AA without any allergic reaction. Epidermal proliferation, induction of angiogenesis, and stimulation of the growth of follicular bulge cells were also reported. Despite showing the efficacy of PRP in AA, it is necessary to carry out randomized clinical trials and long-term evaluations to support the efficacy of therapy.

Keywords: Alopecia areata, platelet-rich plasma, PRP

Cite this Article: Ciptasari, N.W.E. 2020. Role of PRP (platelet-rich plasma) in alopecia areata: A literature review. *Bali Medical Journal* 9(3): 731-736. DOI: [10.15562/bmj.v9i3.2003](https://doi.org/10.15562/bmj.v9i3.2003)

¹Faculty of Medicine, Universitas Udayana

INTRODUCTION

Alopecia areata (AA) is a chronic, scarless hair loss disease that affects specific organs and can affect hair follicles and sometimes nails. Alopecia areata was first recognized as a skin disease by the Ebers Papyrus in 1500-2500 BC. Meanwhile, the term alopecia areata was first used by Sauvages in 1760, which was then published by Lyons in 1760.^{1,2} Based on an epidemiological point of view, this disease affects 0.2% of the total world population. This condition can manifest in the form of small circular patches of hair that fall out to diffuse patches. The area often affected is the scalp.^{2,3} The exact etiology and pathogenesis of AA are currently not fully understood. However, it is believed that the condition is an automatic process through the autoreactive of CD8 + T cells. Several theories about the etiology of alopecia areata, including genetic theory, allergy (atopy), neurophysiological and emotional disorders, endocrine disorders, infection, and several other theories. In the last 30 years, researchers propounded autoimmune theories, which discussed the disruption of humoral and cellular immunity.⁴

Alopecia areata affects the patients physically, psychologically, and cosmetically.² Treatment of AA is not curative, but controls or limits the pathogenesis process. Most treatments are immunosuppressive or immunomodulatory. Intralesional corticosteroid

injection is the most commonly used treatment. Based on overall treatments, the results have not been satisfactory, and the response to therapy varies between individuals.⁵⁻⁷ Platelet-rich plasma (PRP) is a platelet analog in blood plasma concentration. Recently, PRP has been used in the aesthetics and dermatology fields,^{6,7} especially for wound repair.⁸ Use of PRP for AA was reported without an allergic reaction. In alopecia areata, platelets produce growth factors and it acts on stem cells in the hair follicle area, stimulating the development of new hair follicles and neovascularization. PRP acts as an anti-inflammatory agent as well, which decreases cytokine production and inhibits local inflammation in tissues.^{6,7} PRP is also useful as adjuvant therapy in alopecia totalis and universalis.⁵ This literature review will discuss the role of platelet-rich plasma treatment in alopecia areata to understand the concept of PRP treatment including mechanisms, side effects and efficacy to be able to implement it in alopecia areata treatment.

ALOPECIA AREATA

Alopecia areata is a chronic inflammatory disease that affects the hair follicles and sometimes the nails. This disease is characterized by the presence of scarless hair loss that affects all parts of the hair covering the body.⁴

Recently, 1.2% of the world's population has

*Corresponding to:
Ni Wayan Eka Ciptasari;
Faculty of Medicine, Universitas Udayana;
ekaciptasari@yahoo.co.id

alopecia areata, with an estimated risk of 1.7%. It is one of the most common causes of hair loss. However, it is still less common than androgenic alopecia and telogen effluvium. The incidence in men is similar to women. Although it can affect any age, the incidence of young people is greater. AA is the most common form of alopecia reported in children. Genetic involvement was accounted for 15%, which 5% of AA patients developed alopecia totalis, while 1% of patients developed alopecia universalis.^{1,7}

The specific etiopathogenesis of AA remains unknown, but it is believed that the most important role in the autoimmune process. This statement is supported by the presence of lymphocyte infiltration in the affected hair follicle. The ability of immunosuppressive agents to trigger hair growth and the discovery of antigen-presenting cells (macrophages, Langerhans cells) infiltration in dystrophic hair follicles, which believed respond to autoantigen on the hair follicle.⁵ This condition underlines the relationship between alopecia and other autoimmune diseases such as vitiligo, lichen planus, pernicious anemia, diabetes mellitus, and other autoimmune diseases. Alopecia areata is known as an organ-specific autoimmune disease with a genetic predisposition and triggered by environmental factors. The role of genetics in AA is reported on monozygotic twins who experience AA with the same onset and pattern. Specific gene alleles associated with AA include DQ3 (DQB1*03) and DR11 (DRB1*1104), and gene alleles that are significantly associated with alopecia totalis and universalis are DQ7 (DQB1*0301) and DR4 (DRB1*0401). Chromosomal abnormalities that are prone to developing AA include chromosomes 6,10,16, and 18, especially chromosome 6. Alopecia areata is a chronic autoimmune organ-specific disease mediated by autoreactive CD8 + T cells, which attack hair follicles and sometimes nails.^{2,3,9}

Hair bulb in the anagen phase is unable to perform a normal immune response, probably due to triggered interferon- γ , which acts in the pathogenesis of AA. Severe emotional stress prior to experiencing alopecia was found on many patients in several studies. Recent studies have suggested a strong correlation between anxiety disorders and depression as triggering factors for AA.^{4,5}

The diagnosis of AA is generally based on clinical features. The disease is characterized by asymptomatic hair loss, accompanied by the appearance of multiple, non-scar, round patches, varying in number and size, well-defined, no hair (baldness) on it, with a smooth surface in a diffuse distribution.^{1,2,4}

The hallmark of AA is the presence of “black

dots”, which are pigmented and short hairs due to hair damage before reaching the surface of the skin. Another sign is “exclamation point hairs”, which is a dull shape of the hair in the distal and taper on the proximal, thus the damaged hair (black dots) pushing the hair follicles. Several examinations to support the diagnosis are pull tests, pluck tests, skin biopsy, daily hair loss summation, trichoscopy, and other supporting examinations.^{1,2,4,9}

The management of AA is based on the underlying etiology. No definitive treatment is used to treat AA, and treatment is selected based on the course of the disease. Most of the therapeutic modalities have different efficacy and safety levels, although no treatment is curative or preventive.^{2,9} Treatment of chronic alopecia areata is difficult. A combination of more than one type of therapy is required. Platelet-rich plasma (PRP) is a form of adjuvant therapy that has been widely used in the treatment of dermatological disorders, such as alopecia areata. In 2012, an in vivo animal study showed that the injection of activated PRP in the skin of mice every 3 days for 3 weeks showed hair growth improvement. Based on these results, PRP can increase hair growth and hair follicle continuity. PRP increases cell proliferation and has anti-apoptotic properties.¹⁰ For humans, PRP application is widely used for androgenic alopecia, alopecia areata, and surgical procedures.^{4,6-8,10}

PLATELET-RICH PLASMA (PRP)

Platelet-rich plasma (PRP) is an autologous blood product that carries three to five times the normal amount of platelet-rich products. PRP also contains growth factors, chemokines, cytokines, nutritional hormones, stabilizing proteins, such as albumin, and other products that use for cell growth and homeostasis.^{6,7,10}

Over the last few years, PRP has been used in the musculoskeletal field. Recently, these products are used in the fields of dermatology, such as wound healing, fat grafts, alopecia, scar repair, and dermal augmentation. In a normal person, the platelet count is about $1.5-4.4 \times 10^5 / \mu\text{L}$. For limited data studies, the platelet count in PRP cannot be determined. However, for therapeutic effectiveness, a platelet count 4-5 times higher than the lower limit should be achieved at the concentration.^{8,11} Treatment with PRP was first used in 1987 as a blood product used in open-heart surgery. This product was introduced in 1990. PRP was known to be inexpensive and easy-to-use therapy.⁸ The different types of PRP are classified according to the recognized platelet, and fibrin counts are summarized in Table 1.^{8,12}

Platelets are cytoplasmic fragments without a nucleus that are made up of many granules. The cell

membrane contains alpha granules, which play an important role in the storage of intracellular growth factors, such as platelet-derived growth factor (PDGF), transforming growth factor (TGF- β), and insulin-like growth factor (IGF-1), which are important for wound healing. When activated, this alpha granule combines with the platelet cell membrane and activates a number of proteins. This protein will bind to transmembrane receptors on target cells such as epidermal cells, mesenchymal stem cells, and activation of fibroblasts that can induce internal transduction pathways, such as gene expression in cells that functions for cell proliferation, collagen synthesis, anti-apoptosis and others. The types and functions of growth factors on PRP can be summarized in [Table 2](#).^{13,14}

There are various publications indicating the use of PRP in dermatology, for example, in aesthetic surgical procedures, such as face-lifts, cosmetic dermal fat grafts, breast augmentation, hair transplants, chronic skin ulcer, and diabetic ulcers, as topical hemostatic agents, and scar repair.^{13,14}

Contraindications to the use of PRP are patients who have a history of previous coagulation system disorders (e.g., platelet dysfunction,

thrombocytopenia, hypofibrinogenemia), patients with unstable hemodynamics, septicemia, hypersensitivity to bovine thrombin, continuous use of non-steroidal anti-inflammatory drugs in the 48 hours before procedures, injection of corticosteroid into the lesion to be treated or systemic corticosteroid within 2 weeks before the grafting procedure, consumption of anticoagulants or fibrinolytic, fever that has recently improved, cancer affecting the hematopoietic system of bone, hemoglobin level <10 g/dl and pregnant women.^{13,14}

USE OF PRP IN ALOPECIA AREATA

PRP products are applied to the frontal, parietal, and temporal scalp, via subcutaneous and intradermal injection. There are still no definite rules regarding the volume of PRP injected, the time interval for each therapy, and the number of treatments required. The total volume per treatment session varies between 0.8 - 12 ml or about 0.05 - 0.1 ml per cm² of the scalp area to be treated. The average time interval therapy is two weeks to 1 month with the number of therapy 2-5 times.^{7,12} PRP intraoperative injection can be seen in [Figure 1](#).

Table 1. Platelet-rich plasma classification^{8,12}

Abbreviation	Name	Composition
PRP/P-PRP	Pure platelet-rich plasma/ PRP with low leukocytes	Without leucocytes or with density fibrin after activation
PRP/L-PRP	PRP with leukocytes	Leukocytes and low-density fibrin after activation
P-PRF	Pure fibrin rich platelets	Without leukocytes and high-density fibrin
L-PRF	Fibrin-rich leukocyte platelets	Contain leukocytes and high-density fibrin

Table 2. Types of growth factors and their biological functions^{8,14}

Types of growth factors	Biological function
TGF-alpha and beta (transforming growth factor alpha and beta)	<ul style="list-style-type: none"> • Mitogenic factors for mesenchymal cell differentiation • Stimulates fibroblasts, chemotaxis, and myocytes mitogenesis • Regulates collagen production and collagen synthesis • Stimulates macrophages and neutrophil chemotaxis
VEGF (vascular endothelial growth factor)	<ul style="list-style-type: none"> • Increase angiogenesis and permeability of blood vessel • Mitogenic factors for endothelial cell differentiation
CTGF (connective tissue growth factor)	Sanction platelet adhesion
PDGF alpha and beta (platelet-derived growth factor alpha and beta)	<ul style="list-style-type: none"> • Mitogenic factors for mesenchymal cell differentiation • Stimulates fibroblasts, chemotaxis, and mitogenesis of smooth muscle cells • Regulates collagen production and collagen synthesis • Stimulates macrophages and neutrophil chemotaxis
EGF (epidermal growth factor)	<ul style="list-style-type: none"> • Mitogenic factors for mesenchymal cell differentiation • Stimulates chemotaxis of endothelial cell • Regulate collagen synthesis
FGF (fibroblast growth factor)	Mitogenic factors for mesenchymal cell differentiation
IGF-1 (insulin-like growth factor-1)	Stimulate fibroblast chemotaxis and stimulate protein formation

EFFICACY OF PRP IN ALOPECIA AREATA

Generally, three main growth factors in plasma blood platelets, such as platelet-derived growth factor (PDGF), transforming growth factor (TGF), and vascular endothelial growth factor (VEGF). These proteins play an important role in tissue angiogenesis by stimulating healing and the

formation of new organ structures upon contact with other receptors. Fibroblast growth factors 7 (FGF-7) and beta-catenin play a role in stimulating hair growth, which is regulated by the papillary cells of the dermis. The activation of PRP causes the proliferation of papillary cells in the dermis and prevents the apoptosis process and increases the amount of protein Bcl-2, which plays a role in the hair growth cycle. PRP said to promote cell growth and prolong the hair follicle cycle by activating Erk/Akt signals as well. In dermal papilla cells, germinative cells can also be found in the matrix, and activation of a number of growth factors can result in the development of other follicular units, such as the hair shaft, sebaceous glands, erector pilus muscle, and perifollicular. PRP has an anti-inflammatory effect, which reduces the release of cytokines and reduces local inflammatory processes that are useful in the treatment of inflammatory conditions in hair, such as alopecia areata.^{12,15,16}

Several recommendations after receiving PRP treatment including not rubbing, massage, manipulation of the injection site, and avoiding nonsteroidal anti-inflammatory agents (NSAIDs) for at least one to two weeks. NSAIDs inhibit the inflammatory process that already occurs after PRP

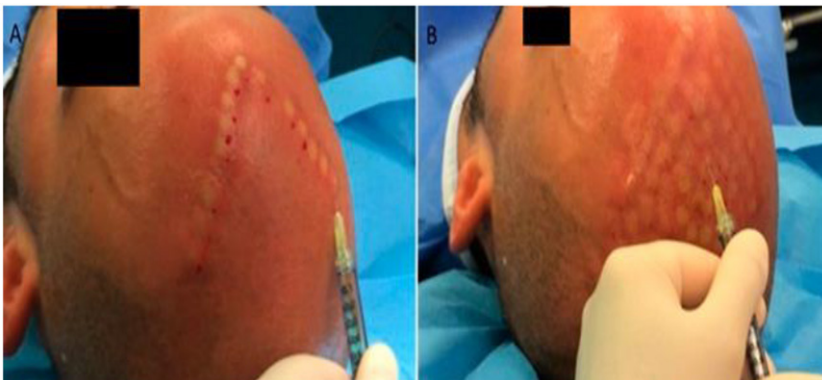


Figure 1. Intraoperative injection with platelet-rich plasma (PRP) (A): Intraoperative injection of 0.1 ml / cm² of PRP in the frontal region. (B): End of PRP injection (0.1 ml/cm²)¹⁷

Table 3. Autologous PRP studies for treating hair loss^{16,18-20}

Studies	Subject number	Formula	Treatment amount	Treatment interval	Main result	Side effect
Singhal et al.	10	Autologous PRP, 8-12 ml every treatment	4	2 weeks	<ul style="list-style-type: none"> 10/10 treated patients showed improvement globally compared to controls 65% showed a decrease in hair pull test in the treated group compared to the control 	Mild headache
Gentile et al.	23	Autologous PRP, 0,1 ml/cm ² every treatment	3	4 weeks	<ul style="list-style-type: none"> Significant increase in hair count, total hair density, and terminal hair density compared to baseline Increased epidermal thickness and increased number of hair follicles in PRP-treated patients compared to baseline 	None
Cervelli et al.	10	Autologous PRP, 0,1 ml/cm ² every treatment	3	4 weeks	<ul style="list-style-type: none"> Hair density and mean hair count increased significantly compared to baseline therapy Increase in the thickness of the epidermis and the number of hair follicles within 3 months Increased blood vessels around the hair in PRP-treated patients 	None
Maria-Angeliki et al.	20	Activated autologous PRP with gluconate calcium	3	3 weeks, booster on 6 months	<ul style="list-style-type: none"> Hair density (hair/cm²) increased compared to the baseline The highest hair density occurs at the 3rd month The patient satisfaction rate of 85% based on hair quality and thickness 	Mild pain and sensitivity of the scalp

therapy. Patients are allowed to wash their hair after 3 hours of therapy using shampoo, avoid activities that produce a lot of sweat in two days, avoid hair coloring and hair straightening within 3 days.^{14,16,17}

Therapeutic efficacy has not been reported in both gender, thus it is difficult to differentiate between male and female baldness. Most studies have not followed clinical improvement beyond 6 months. Despite the histological features, the investigators concluded that PRP could increase epidermal proliferation, stimulate the follicular bulge cells growth, and induce angiogenesis, although this statement remains unclear.^{6,23} Another study was also conducted in 2015, out of 30 subjects treated with PRP, 21 subjects (70%) experienced complete hair growth, while 9 subjects (30%) experienced partial hair growth (Figures 2 and 3).⁶

PRP SIDE EFFECTS

The side effects reported were only mild and transient minimal pain at the injection site. Several studies have used lidocaine before injection,

although other studies have rejected the injection of this substance because it increases discomfort. There have been no reports of bacterial, viral, and mycobacterial infections, folliculitis, panniculitis, hematoma or seroma formation, increased number of hair loss, changes in sensory nerves, and formation of scars.^{7,8} Natural autologous administration of PRP is said to be safe because there is no potential risk of transmitting some disease versus using blood products from donors. There are no studies showing the potential for malignancy due to the use of PRP.^{24,25}

PRP INTERACTIONS WITH OTHER THERAPIES

In a double-blind, randomized study, PRP could be combined with triamcinolone acetonide (TA) in the treatment of chronic alopecia areata. Changes are found in the SALT (severity of alopecia tool) score, and a dermoscopic examination can reveal a reduction in dystrophic hair. PRP, in combination with TA injection, can increase terminal hair and hair fiber diameter. Researchers conclude that PRP has a positive effect when combined with TA injection in the treatment of alopecia areata.²⁶

Several studies have investigated the effect of PRP in combination with minoxidil on the treatment of alopecia areata. Minoxidil is a vasodilator that increased vascular endothelial growth factor (VEGF) mRNA in the papillary dermis and cytoprotective prostaglandin synthase-1, an enzyme that stimulates hair growth and increases the release of hepatocyte growth factor (HGF) mRNA, which also plays a role in hair growth. In a 2016 Indian study on 60 patients, it was shown that the combination of minoxidil and PRP therapy was more effective than monotherapy with minoxidil in increasing hair volume and quality.²⁷

CONCLUSION

Alopecia areata is a form of autoimmune hair loss without scarring, which affects the scalp with or without affecting the body. Treatment of AA based on the underlying disease. PRP therapy was introduced as an adjuvant therapy modality in AA, especially chronic alopecia areata. This therapy is easy to do and effective in AA, without side effects, and might offer useful therapies in AA. Although several studies have shown the efficacy of PRP therapy in AA, further randomized clinical trials need to be done to support the efficacy of this therapy. Concentration standards and preparation methods of PRP are also needed in order to produce a homogeneous PRP product.

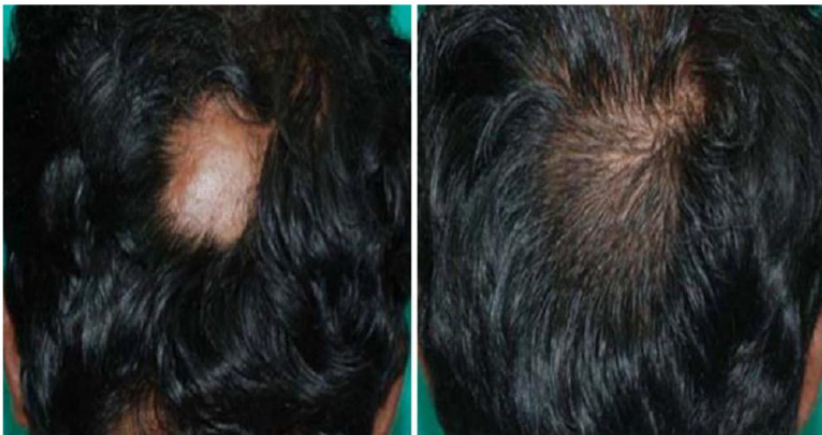

Figure 2. Alopecia areata on a 24-year-old man, before and after 3 months of PRP⁶

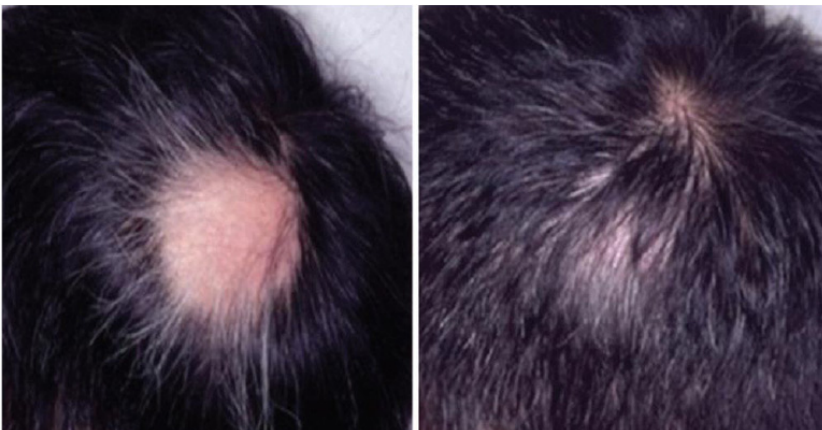


Figure 3. Results of 3 months of PRP in a 26-year-old man⁶

CONFLICT OF INTEREST

The author declares there is no conflict of interest regarding this publication.

AUTHORS CONTRIBUTION

All authors contributed to the preparation of this literature review.

FUNDING

None.

REFERENCES

1. Otberg N, Shapiro J. Non-Scarring Focal Hair Loss. In: Hair Growth Disorders. Goldsmith LA, Katz SI, Gilchrist BA, Paller AS, Leffell DJ, Wolff K, editors. *Fitzpatrick's dermatology in general medicine*, 8th ed. New York: McGraw-Hill; 2012. 991-994.
2. Amin SS, Sachdewa S. Alopecia areata: A review. *Journal of the Saudi Society of Dermatology and Dermatologic Surgery*. 2013;17:37-45.
3. Hordisky MK. Overview of Alopecia Areata. *The society of Investigative Dermatology*. 2013;16:1-2.
4. Signal A, Sonthania S, Verma P. Female Pattern Hair Loss. *Indian Journal of Dermatology, Venereology and Leprology*. 2013;79(5):627-640.
5. Ovidio RP. Alopecia Areata: A News On Diagnosis, Pathogenesis, and Treatment. *G Ital Dermatology Venereology*. 2014;149:25-45.
6. Kumar A, Sharma RP. Role of Platelet Rich Plasma Therapy in Alopecia Areata-A Prospective Study. *International Journal of Contemporary Medical Research*. 2016;3(8):2499-2502.
7. Langer C, Mahajan V. Platelet-Rich Plasma in Dermatology. *JK Science*. 2014;16(4):147-149.
8. Labusca LS, Cionca D. Clinical Review about the Role Of Platelet Rich Plasma for the Treatment of Traumatic and Degenerative Musculoskeletal Disorders. *Orthopedics and Rheumatology Journal*. 2016;2(3):1-9.
9. Wang E, Kevin J. Etiopathogenesis of Alopecia Areata; Why Do Our Patients Get It. *Dermatologic Therapy*. 2011; 24: 337-347.
10. Li ZJ, Choi HI, Choi DK, Sohn KC, Im M, Seo YJ, Lee YH, Lee JH, Lee Y. Autologous platelet-rich plasma: a potential therapeutic tool for promoting hair growth. *Dermatol Surg*. 2012;38(7 Pt 1):1040-6.
11. Montero EC, Santos F, Fernandez S. Platelet-Rich Plasma: Application in Dermatology. *Actas Dermosifiliogr*. 2015;106(2):104-111.
12. Marlovits S, Mousavi M, Gabler C, Erdos J, Vecsei V. A new simplified technique for producing platelet-rich plasma: a short technical note. *Eur Spine J*. 2004;13(Suppl 1):S102-106.
13. Uebel CO, Escobar PD. Follicular Unit Megassessions and Platelet Growth Factor. *Rev Bras Ur Plast*. 2013;281:154-164.
14. Sammeling CE, Heyneman A. The Use of Platelet-Rich Plasma in Plastic Surgery, A Systemic Review. *Journal of Plastic Reconstruction and Aesthetic Surgery*. 2013;66:301-312.
15. Gentile P, Garcovich S, Bielli A. The Effect of Platelet Rich Plasma in Hair Regrowth ; A Randomized Placebo-Controlled Trial. *Stem Cells Translational Medicine*. 2015;4:1317-1323.
16. Lynch Md, Baschirs. Application of Platelet-Rich Plasma in Dermatology: a Critical Appraisal of The Literature. *Journal of Dermatology Treatment*. 2016;27(3):283-289.
17. Fukaya M, Ito A. A New Economic Method for Preparing Platelet-rich Plasma. *Plast Reconstr Surg Glob Open*. 2014;2(6):1-7.
18. Singhal P, Agarwal S, Dhot PS, Sayal SK. Efficacy of platelet-rich plasma in treatment of androgenic alopecia. *Asian J Transfus Sci*. 2015;9(2):159-62.
19. Cervelli V, Garcovich S, Bielli A, Cervelli G, Curcio BC, Scioli MG, Orlandi A, Gentile P. The effect of autologous activated platelet-rich plasma (AA-PRP) injection on pattern hair loss: clinical and histomorphometric evaluation. *Biomed Res Int*. 2014;2014:760709.
20. Maria-Angeliki G, Alexandros-Efstratios K, Dimitris R, Konstantinos K. Platelet-rich Plasma as a Potential Treatment for Noncicatricial Alopecias. *Int J Trichology*. 2015 Apr-Jun;7(2):54-63.
21. Messura MR, Nagata MJ. A Standardized Research Protocol for Platelet-Rich Plasma (PRP) Preparation in Rats. *Original Research Article*. 2011;8(3):299-304.
22. Maazoca DA, Beth M. Platelet-Rich Plasma Differs According to Preparation Method and Human Variability. *The Journal of Bone and Joint Surgery*. 2012;94(4):308-316.
23. Dhillion SR, Schaward EM. Platelet-Rich Plasma Therapy Future or Trend. *Arthritis Research and Therapy*. 2012;14:1-10.
24. Sommeling CE, Heyreman A. The Use of Platelet-Rich Plasma in Plastic Surgery: A Systematic Review. *J Plast Reconstr Aesthet Surg*. 2013;66:301-313.
25. Cole BJ, Soreyer ST. Platelet-Rich Plasma: Where Are Now And Where Are We Going. *Sport Health Medicine*. 2010;10(10):1-8.
26. Mubki T. Platelet-rich plasma combined with intralesional triamcinolone acetonide for the treatment of alopecia areata: A case report. *Journal of Dermatology and Dermatology Surgery*. 2016;20:87-90.
27. Uzzaif M, Vaaruni R. A Comparative Study of Treatment Modalities in Female Alopecia Areata. *International Journal of Research in Medical Sciences*. 2016;4(4):1229-1236.



This work is licensed under a Creative Commons Attribution