

LAMINOPLASTY FUSION FOR CERVICAL SPINAL CORD INJURY WITH OSSIFICATION OF POSTERIOR LONGITUDINAL LIGAMENT: Combination technique for better result (Case Series)

T. G. B. Mahadewa

Neurosurgery Department, Faculty of Medicine, Udayana University/Sanglah General Hospital,
Bali-Indonesia

Background: This was a retrospective study of 10 cervical spinal cord injury (CSCI), concomitant with ossification of posterior longitudinal ligament (OPLL), that were treated by the author at Sanglah General Hospital-Bali during 2013-2014. The purpose of this study was to evaluate the efficacy of combination technique of laminoplasty with lateral mass screw fusion for canal compression due to OPLL in CSCI. There were 9 male patients of 10, average age was 58,3 years old. American Spinal Cord Injury Association (ASIA) scale preoperative was average in C scale and ASIA scale postoperative was in D. Mean JOA score preoperative was 9,5 and mean Japan orthopedic association (JOA) score postoperative was 13,3. Improvement after surgery using improvement formula of JOA was achieved by mean of 19,16%. All patients survived and improved neurologically, there was no surgical complication and implant failure in this series. No kyphotic deformity was observed in follow up cervical spine x-ray after 6 months. The author present a combination technique of 10 consecutive patients who underwent laminoplasty fusion for OPLL in CSCI with better result.

Keywords: cervical; spinal; cord; complication; kyphotic.

INTRODUCTION

Laminectomy fusion and stabilization is well accepted for the treatment of cervical spinal instability due to cervical injury.¹ Hadra firstly explained the use of wiring technique to treat cervical instability for Pott's disease and traumatic fracture.² Recently, lateral mass screw system is wide accepted for better stabilization in posterior cervical spine.¹ Meanwhile, laminoplasty was preferred to decompress cervical canal stenosis due to ossification of posterior longitudinal ligament (OPLL).³ Laminoplasty was started in Japan in the 1970s as a recent technique to laminectomy for cervical decompression, that prevent many complication associated with laminectomy, in better neurological outcome.²⁻⁴

In case of OPLL in CSCI, the surgeon must decide to do laminectomy fusion or laminoplasty. The goal is, not only to provide adequate cervical canal decompression but also assured posterior cervical stabilization because of trauma related fracture, facet injury and posterior ligaments incompetence.^{1,3} Both techniques can provide

adequate posterior cervical cord decompression but using laminectomy in swelling cord and narrow spinal canal, due to OPLL, can produce further injury to the cord and deteriorate the neurological status. Meanwhile, using laminoplasty in uncertain cervical stability due to complex injury mechanism can worsen its stability. Combination technique of laminoplasty and fusion using lateral mass screw system was considered.

The preoperative neurological conditions are reported using ASIA scale and compared postoperatively. JOA score, for measuring improvement in minimum 6 months of follow up period, were evaluated. Radiological findings and operative techniques are reported as well.

CLINICAL MATERIAL AND METHODS

Patient population

Ten patients who had concomitant OPLL with CSCI underwent laminoplasty Hirabayashi type augmented miniplate and fusion with instrumented lateral mass screw and rod system by single author between March 2013 and October 2014. All patients were treated conservative for 2 weeks and failed to improve following treatment with hard collar, steroids, nonsteroid antiinflammatory drug and physiotherapy and comprehensive preoperative evaluation including cardiopulmonary and existing metabolic disease. Preoperative radiographic

Address of correspondence:

T. G. B. Mahadewa, MD.Ph.D.

Associate Professor of Neuro Surgery, University of Udayana, Division of Neurospine, Sanglah General Hospital, Bali-Indonesia.

E-mail: tjokmahadewa@hotmail.com

examination including plain cervical spine x-ray, cervical computed tomography (CT) scan and magnetic resonance (MR) imaging were carried out. Cervical fracture dislocation, obvious cervical unstable ligamentous injury, non OPLL spondylotic cervical and laminectomy indicated case were excluded.

All patients had an acute cervical spinal cord injury without cervical myelopathy symptoms previous injury. All patients underwent combination laminoplasty fusion technique. All patients used hard collar for 2 months and continued physical therapy for 6 months. Plain cervical x-ray were obtained on day 3 postoperatively and after 6 months follow up. Follow up CT scan were obtained in 8 weeks postoperatively and a minimum 6 months of follow up were done in all patients (range 6-25 months). The neurological status were recorded using ASIA and JOA score after 6 months follow up and compared to the preoperative condition.

ASIA scale is a standard method of assessing the neurological status of a person who has suffered from spinal cord injury (Table 1). The Japanese Orthopaedic Association scoring system for the evaluation of cervical myelopathy (JOA score) was first established by a committee of the JOA chaired by Hirabayashi.^{5,6} Since then, this scoring system has been accepted universally in Japan as a scoring to measure the outcomes of various cervical spinal disorders that cause cervical myelopathy Modified by Keller 1993 as can be seen in Table 2.⁷

Table 1
ASIA impairment scale⁵

Category	Description
A = Complete	No motor or sensory function (for definitions, see note below) is preserved in the sacral segments S4-S5
B = Incomplete	Sensory but not motor function is preserved below the neurological level and includes the sacral segments S4-S5
C = Incomplete	Motor function is preserved below the neurological level, and more than half of key muscles below the neurological level have a muscle grade of less than 3
D = Incomplete	Motor function is preserved below the neurological level, and at least half of the key muscles below the neurological level have a muscle grade of 3 or more
E = Normal	Motor and sensory function are normal.

Operative Technique

Under general anesthesia the patient was placed in prone position, the head and neck were immobilized and standard midline incision was made to exposed lamina of C2 until C7.

Table 2

The Japanese Orthopaedic Association scoring system for the evaluation of cervical myelopathy (JOA score)

Criterion	Point
Motor fuction	
Paralysis	1
Fine motor function massively decreased	2
Fine motor function decelerated	3
Discreet weakness in hands or proximal arm	4
Normal function	5
Motor function	
Unable to walk	1
Need walking aid on flat floor	2
Need handrail on stairs	3
Able to walk without walking aid, but inadequate	4
Normal function	5
Sensory Upper extremity/lower extremity/trunk	
Apparent sensory loss	1
Minimal sensory loss	2
Normal function	3
Bladder function	
Urinary retention	1
Severe dysfunction	2
Mild dysfunction	3
Normal function	4

Postoperative improvement in percent of JOA score:⁷

$$((\text{postoperative score}) - (\text{preoperative score}) / (29 - (\text{preoperative score})) \times 100\%$$

Subperiosteal dissection was done and automatic spreaders were placed. Medial margin of facets was marked and drilling using highspeed drill (Aesculaps, USA) until the cancelous bone on the right side and drilling until inner cortex on the left side for open door model. Using Kerrison ronger 3 mm the left side were lifted slowly, any sublaminar adhesion was dissected free. The author preferred to open the left side "door" as a righthanded surgeon preference. Polyaxial lateral mass crews (GS Medical, Korea) were screwed 1 level above and below laminoplasty level. The size of the screws generally range from 14-16 mm in length and all screws in 3.5 mm diameter. Titanium miniplate (Osteomed, USA) was augmented to hold the opening door securely using autodrill screws

size 5 mm in length and 1.5 mm in diameter and collagen synthetic (Suprasorb-C) filled the space of the open door. After the rod screws system were tighten and hemostasis was confirmed, a 10 F vacuum drain was placed and wound was closed layer by layer in usual fashion (Figure 1).

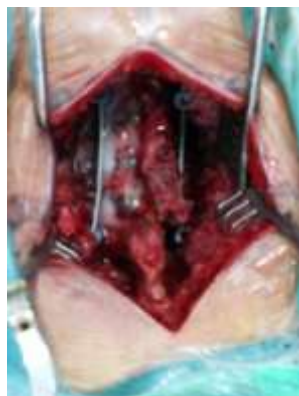

Figure 1

Intraoperative view of C4-6 laminoplasty with lateral mass screw fusion C3-7

RESULTS

In this series, the patients were 9 male and 1 female. Mean of age was 58.3 years old. All patients had neck trauma with concomitant cervical OPLL were examined neurologically by ASIA scale, preoperative range of A to D; 2 pts with ASIA A, 1 pt with ASIA B, 4 pts with ASIA C and 3 pts with ASIA D. Functionally were checked using JOA score, preoperative range of 4 to 10. The preoperative ASIA Scale pre and postoperative of these 10 patients are shown in Table 3.

Table 3
Pre and postoperative ASIA scale in 10 patients CSCI with OPLL

Time	ASIA Scale					Ave
	A	B	C	D	E	
Pre	2	1	4	3	0	C
Post	0	1	1	4	4	D

Ave = average

Mean JOA score preoperative was 9.5 and mean JOA score postoperative was 13.3. Improvement after surgery using improvement formula was achieved by mean of 19.16% (Table 4). In short term surgical outcome was improved in all patients, no infection, no cerebrospinal fluid leak, no nerve root palsy and implant failure was observed in this series was found. No kyphotic deformity was observed in follow up cervical spine x-ray after 6 months (Figure 2)

DISCUSSION

Cervical cord compression due to OPLL can cause significant cord injury when neck injury

happen. Laminectomy decompression fusion using lateral mass screws is appropriate for neck spine injury while laminoplasty i.e one door laminoplasty using miniplate screws is advocated for cord compression due to OPLL. To date there is no guideline for the treatment of neck spinal cord injury with concomitant OPLL. The authors used combination of techniques to gain better outcome as the background of the study.

Table 4
Pre and postoperative JOA score in 10 patients CSCI with OPLL

Patients	JOA		Improvement
	Pre	Post	
1	9	12	15
2	10	13	15.8
3	7	16	40.9
4	10	13	15.8
5	9	12	15
6	4	8	16
7	14	17	20
8	15	17	14.3
9	13	16	18.8
10	4	9	20
Mean	9.5	13.3	19.16

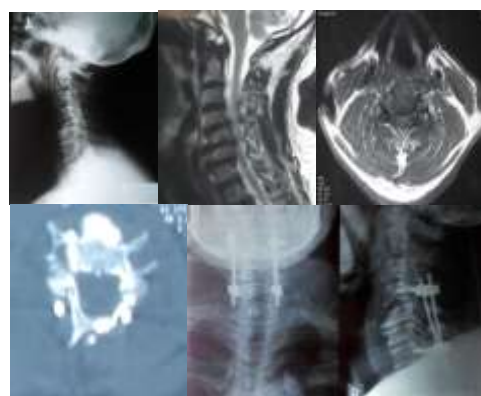


Figure 2

Radiographics obtained in a 60-year-old man was diagnosed as CSCI ASIA D and JOA score 14 preoperatively with improvement after surgery. **Upper:** preoperative plain x-ray film (upper left) and MRI T2WI (upper middle and right) showing decreased spinal canal diameter and OPLL from C2-6 with narrowing subarachnoid space. **Lower:** postoperative CT scan (lower left) showing enlargement of spinal canal diameter. AP view cervical spine x-ray (lower middle) showed lateral mass screws on C4,C7 and augmented miniplate on laminoplasty at C5-6. Lateral view cervical spine x-ray (lower right) showed no further kyphotic deformity which obtained 6 months after laminoplasty fusion.

Laminoplasty is believed to be the main choice of treatment of multilevel cervical canal stenosis, mainly with the presence of myelopathy, due to OPLL and cervical canal stenosis. However, different treatment in the event of traumatic cervical spinal cord injury, with the generally severe edema in the acute phase and issue of instability, so that a total laminectomy with fusion using instrumentation is preferred. Actually posterior decompression can be achieved by laminectomy or laminoplasty, both techniques are sufficient for decompression but each technique has a weakness and potential complication. Laminectomy can cause postlaminectomy instability, progressive kyphotic deformity, late neurological deterioration and postlaminectomy membrane.^{8,9} Laminoplasty has also a potential complications, as reported by John and Paul in 2003, worsening of cervical alignment, decreased cervical Range of Motion (ROM), and postoperative kyphosis.³

Problems arise when performing laminectomy in the acute phase in which the laminectomy manipulation is currently believed make excessive emphasis on the cord that already squashed by OPLL, which resulted in deterioration postoperatively. Softer decompression can be done by doing laminoplasty but in acute phase, neck injury compromise the bones, joints and ligaments make the surgeon doubt regarding the stability of the cervical segment. Departing from the above discussion, the authors combine the two techniques by laminoplasty so decompression can be done without pressing the medulla as well do the fusion using lateral mass screw and rod system. This construction ensuring the stability of the cervical spine and prevent postoperative kyphosis. There were 10 patients in this report. Good result in short term regarding improved neurological condition (Improvement in JOA score by 19,16%), better ASIA scale that observed average in D scale after follow up, no surgical complications and no further kypothic deformity was observed in this series.

In conclusions, this small series encourage the author to use combination technique of laminoplasty fusion and collecting more cases for statistical analysis in better study design.

REFERENCES

1. James K. L., Kaushik D. 2001. Posterior fusion of the subaxial cervical spine: indications and techniques. *Neurosurg Focus* 10 (4): Article 7,
2. Hadra B. E. Wiring the spinous processes in Pott's disease. *Trans Am Orthop Assoc* 4:206-210,1891.
3. John K. R., Paul R. C. 2003. Cervical laminoplasty: a critical review. *J Neurosurg (Spine3)* 98: 230-238.
4. Takayasu M., Takagi T., Nishizawa T., et al. Bilateral open door cervical expansive laminoplasty with hydroxyapatite spacers and titanium screws. *J Neurosurg (Spine1)* 96:22-28, 2002.
5. Asia Impairment scale. Available at http://www.acc.co.nz/for-providers/clinical-best-practice/spinal-injury-guidelines/PRD_CTRB091020
6. Mitsuru F., Kazuhiro C., Mamoru K., et al. Japanese Orthopaedic Association Cervical Myelopathy Evaluation Questionnaire (JOACMEQ): part 4. Establishment of equations for severity scores. *J Orthop Sci* 13(1): 25-31,2008.
7. Japanese Orthopaedic Association (JOA). Japanese Orthopaedic Association Assessment Criteria Guidelines Manual. Pp 46-49. 1996.
8. Epstein J. A.. The surgical management of cervical spinal stenosis, spondylosis and myeloradiculopathy by means of the posterior approach. *Spine* 13:864-9, 1988.
9. Saito T., Yamamuro T., Shikata J., et al. Analysis and prevention of spinal column deformity following cervical laminectomy. I. Pathogenetic analysis of postlaminectomy deformities. *Spine* 16:494-502, 1991.

